



Silver-haired bat rabies virus variant does not induce apoptosis in the brain of experimentally infected mice

Xiuzhen Yan,¹ Mikhail Prosnik,² Mark T Curtis,³ Mark L Weiss,⁴ Milosz Faber,² Bernhard Dietzschold,² and Zhen F Fu¹

¹Department of Pathology, The University of Georgia, Athens, Georgia, USA; ²Department of Microbiology and Immunology; and ³Department of Pathology, Anatomy and Cell Biology, Thomas Jefferson University, Philadelphia, Pennsylvania, USA; and ⁴Department of Anatomy and Physiology, Kansas State University, Manhattan, Kansas, USA

To examine whether induction of apoptosis plays a role in the pathogenesis of street rabies, we compared the distribution of viral antigens, histopathology, and the induction of apoptosis in the brain of mice infected with a street rabies virus (silver-haired bat rabies virus, SHBRV) and with a mouse-adapted laboratory rabies virus strain (challenge virus standard, CVS-24). Inflammation was identified in the meninges, but not in the parenchyma of the brain of mice infected with either CVS-24 or SHBRV. Necrosis was present in numerous cortical, hippocampal, and Purkinje neurons in CVS-24-infected mice, but only minimal necrosis was identified in mice infected with SHBRV. Likewise, extensive terminal deoxynucleotidyl transferase-mediated dUTP-digoxigenin nick end-labeling (TUNEL) staining was observed in the brain of mice infected with CVS-24 but little or none in the brain of mice infected with SHBRV. Rabies virus antigens were distributed similarly in the CNS infected with either virus. However, the expression of the glycoprotein (G) is more widespread and the staining of G is generally stronger in CVS- than SHBRV-infected mice, whereas the expression of rabies virus nucleoprotein (N) is similar in mice infected with either CVS or SHBRV. The positive TUNEL staining thus correlates with the high level of G expression in CVS-infected mouse brain. Northern blot hybridization revealed that the ratio between the N and G transcripts is similar in brains infected with either virus, indicating that the reduced expression of G protein is not caused by reduced transcription in SHBRV-infected animals. Taken together, these observations suggest that apoptosis is not an essential pathogenic mechanism for the outcome of a street rabies virus infection and that other pathologic processes may contribute to the profound neuronal dysfunction characteristic of street rabies. *Journal of NeuroVirology* (2001) 7, 518–527.

Keywords: rabies virus; apoptosis; necrosis; neuropathogenicity; TUNEL

Introduction

The rabies virus is almost exclusively neurotropic *in vivo* (for a review, see Dietzschold *et al*, 1996). Humans usually become infected with the rabies virus through animal bites (Dietzschold *et al*, 1996) or, in rare occasions, by mucosal exposure (Constantine,

1962). The virus enters the peripheral nervous system from the site of the bite by binding to specific neural receptor(s) (Lentz *et al*, 1982; Thoulouze *et al*, 1998; Tuffereau *et al*, 1998). Once inside neurons, the rabies virus replicates and spreads to the central nervous system (CNS). Almost all neurons in the brain can become infected with the virus (Murphy, 1977; Iwasaki, 1991; Smart and Chalton, 1992). However, the mechanism by which rabies virus infection of the CNS causes neurological disease and death is not completely understood. Rabies patients develop severe agitation, depression, hydrophobia, and paralysis followed by impaired consciousness and coma (Hemachudha, 1994). Patients eventually

Address correspondence to Zhen F Fu, Department of Pathology, College of Veterinary Medicine, The University of Georgia, D.W. Brooks Drive, Athens, GA 30602-7388, USA. E-mail: zhenfu@vet.uga.edu

Received 14 May 2001; accepted 16 August 2001.

die of circulatory insufficiency, cardiac arrest, and respiratory failure (Tirawatpong *et al*, 1989; Hemachudha, 1994). Postmortem examination of human rabies patients reveals few gross pathologic lesions in the brain, other than a variable degree of cerebral edema (Murphy, 1977). Histopathology of the brain does not offer a satisfactory explanation for the lethality of rabies. Microscopic lesions and inflammatory reactions are mild with relatively little neuronal destruction (Miyamoto and Matsumoto, 1967; Murphy, 1977). Thus, fatal rabies may result from functional alterations of neurons rather than from structural damage (Tsiang, 1982).

Recently, apoptosis has been suggested as a pathogenic mechanism for rabies. Infection of mouse neuroblastoma cells (Jackson and Rossiter, 1997); human and mouse lymphocytes (Jackson and Rossiter, 1997; Thoulouze *et al*, 1997); or rat prostatic adenocarcinoma cells (Jackson and Rossiter, 1997) with laboratory-adapted rabies virus strains, such as the challenge virus standard (CVS) or Evelyn Rokitnicki Ableseth (ERA), resulted in apoptosis. Infection of suckling and adult mice with CVS or Pasteur strain also lead to extensive apoptosis in rabies virus-infected CNS (Jackson and Rossiter, 1997; Jackson and Park, 1998; Theerasurakarn and Ubol, 1998; Galelli *et al*, 2000). However, Morimoto *et al*, (1999) reported that CVS-N2c, the highly pathogenic strain that was derived from CVS-24, induced significantly less apoptosis in primary neuronal cultures than CVS-B2c, the low pathogenic variant also derived from CVS-24. These investigators suggested that apoptosis contributes to protection rather than pathogenicity in rabies virus-infected animals.

In the present study, we examined the virus distribution, histopathologic lesions, and induction of apoptosis in the brain of mice infected with a mouse-adapted laboratory strain (CVS-24) or with a street rabies virus strain associated with silver-haired bats (SHBRV). SHBRV has been associated with most of the indigenous human cases in the United States during the past decade (see Dietzschold *et al*, 2000; MMWR, 2000). We found that although the CVS-24 induced neuronal necrosis and apoptosis in the brain, the street virus SHBRV induced only mild histological changes and little or no apoptosis in the brain. These observations suggest that apoptosis may not be an essential pathogenic mechanism for rabies induced by street rabies virus.

Results

Mice infected with SHBRV developed clinical signs of rabies one day earlier than those infected with CVS-24

It has been shown previously that SHBRV-18 is the most pathogenic virus among the bat viruses as defined by the pathogenic index (Dietzschold

et al, 2000). In the present study, mice infected with SHBRV exhibited characteristic clinical signs, such as ataxia, seizures, and paralysis, on days 3 or 4 p.i., an average of 1 day earlier than those infected with CVS-24 (on days 4 or 5 p.i.). All animals were euthanized when moribund, usually at days 5 or 6 after infection.

Neuronal necrosis was observed in the brain of mice infected with CVS-24 but not in mice infected with SHBRV

Brains of mice infected with CVS-24 and with SHBRV both had meningeal lymphocytic inflammation and spongiform change in the neuropil (data not shown). Infiltration of inflammatory cells in the parenchyma of the brains was not apparent in mice infected with either virus. However, neuronal necrosis was identified in different brain regions of two mice infected with CVS-24 (Figure 1). Necrosis was observed primarily in pyramidal neurons in the hippocampus, Purkinje neurons in the cerebellum, and in neocortical neurons. Necrotic changes were much milder in the other two mice infected with CVS-24. In contrast, very little or no neuronal necrosis was observed in the brain in any of the mice infected with SHBRV (Figure 1).

Positive terminal deoxynucleotidyl transferase-mediated dUTP-digoxigenin nick end-labeling (TUNEL) staining was observed in the brain of mice infected by CVS-24 but not SHBRV

TUNEL-positive staining was widespread in brain regions, particularly in the hippocampus and the cerebral cortex, in two of the mice infected with CVS-24 (Figure 2). In addition, TUNEL-positive staining was more sporadic in the other two mice infected with CVS-24. In one of the mice, the TUNEL staining was most prominent in areas of the brain where necrotic neurons were identified on hematoxylin and eosin-stained sections. In contrast, very little TUNEL staining was observed in the brains in any of the mice infected with SHBRV (Figure 2). Similar observations were made using a different SHBRV isolate (SHBRV-17; data not shown). TUNEL-positive neurons had strong staining of the nucleus and multiple nuclear condensation of chromatin (Figure 3). Such apoptotic changes were observed only in CVS-24-infected mice.

The overall distribution of SHBRV and CVS-24 antigens was similar in the brain but the expression of the G protein is more widespread and the level of G expression was stronger in mice infected with CVS-24 than in mice infected with SHBRV

Rabies virus antigens were initially detected using anti-rabies virus G polyclonal antibodies. Rabies virus antigen was present in almost all parts of the brain, including striatum, cortex, hippocampus, diencephalon, medulla, brain stem, and cerebellum. As shown in Figure 4, viral antigens were distributed

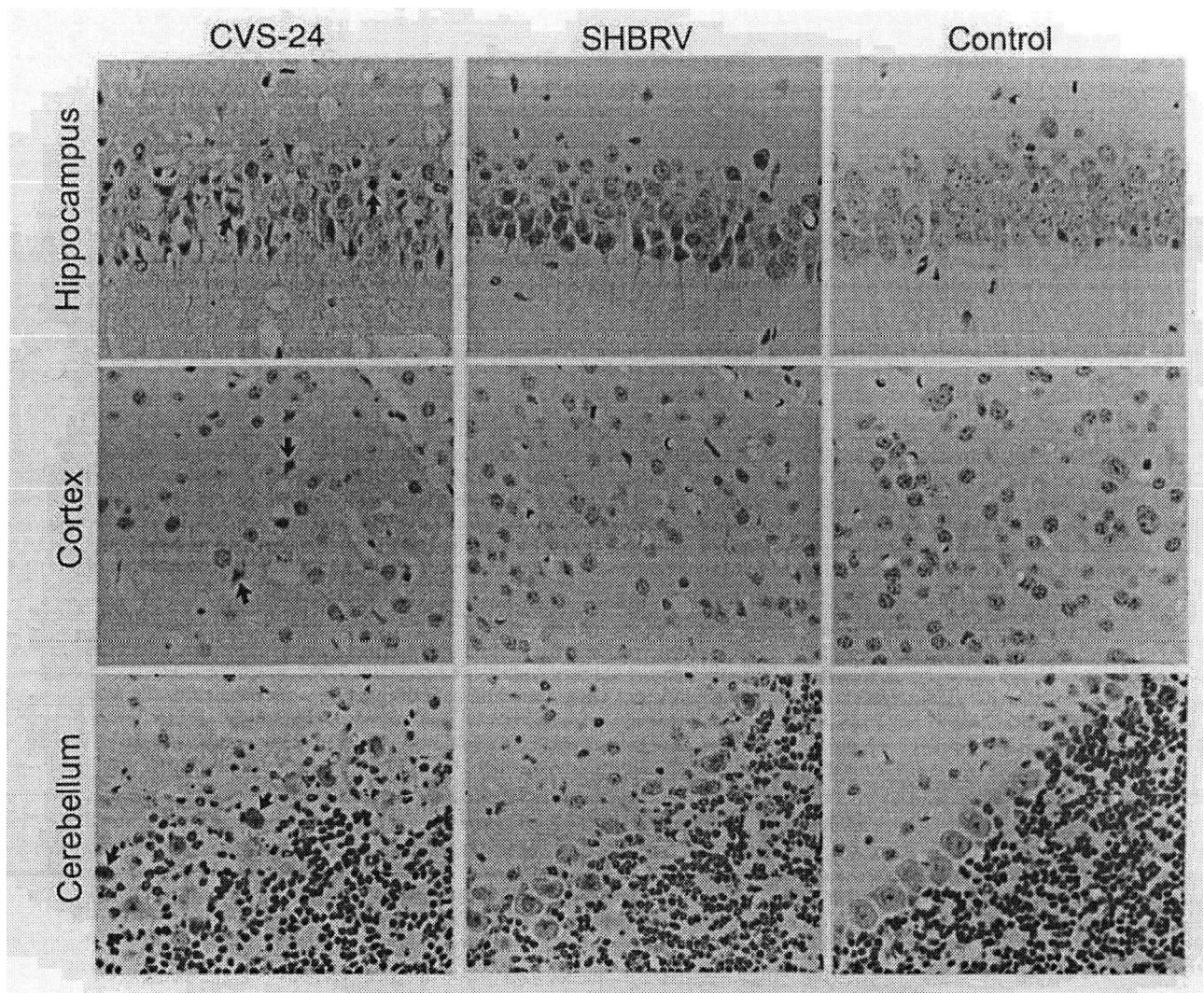


Figure 1 Pathological changes in the CNS of mice infected with CVS-24 and SHBRV. Mice were infected with either CVS-24 or SHBRV. Mice were perfused and the brains were taken for histology. Some of the necrotic neurons are indicated by arrows. (Hematoxylin and eosin, 400 X.)

similarly in SHBRV and CVS-24-infected brains. For example, pyramidal neurons in the hippocampus were infected (Figures 4 and 5), whereas granular neurons in the dentate gyrus were not (Figure 5). Likewise, Purkinje neurons in the cerebellum were infected whereas neurons in the granular layer were infected only rarely (data not shown). The expression of G was more widespread in CVS- than in SHBRV-infected brain (Figure 4). When both anti-G and anti-N antibodies were used in detecting rabies virus antigens, it was found that the intensity of the immunostaining of the rabies virus G protein was stronger in the hippocampus of mice infected with CVS-24 than in mice infected with SHBRV (Figure 5). The immunostaining of the N protein in the hippocampus of mice infected with CVS-24 was similar to or slightly less intense than in SHBRV-infected mice (Figure 5). TUNEL-positive staining was only observed in the hippocampus of

CVS-infected mice (Figure 5), suggesting that induction of apoptosis correlates with the higher level of G expression.

To confirm that the reactivity of the G polyclonal antibodies is similar to the G protein of CVS-24 and the G protein from SHBRV, the respective G proteins were *in vitro* translated and labeled with ³⁵S-methionine. Initially, the synthesized proteins were precipitated by 10% TCA and 102100 CPM of CVS-N2c G and 138550 CPM of SHBRV G were obtained. After immunoprecipitation with the polyclonal anti-G antibody, 52690 CPM of CVS-N2c G and 80636 CPM of SHBRV G were precipitated, representing 52 and 58% of the total protein subjected to immunoprecipitation, respectively. These proteins (25803 CPM of CVS-N2c G and 29100 CPM of SHBRV G) were further analyzed by 10% SDS-PAGE. Similar pixels (532913 and 665004) above background were determined for CVS-N2c G and for

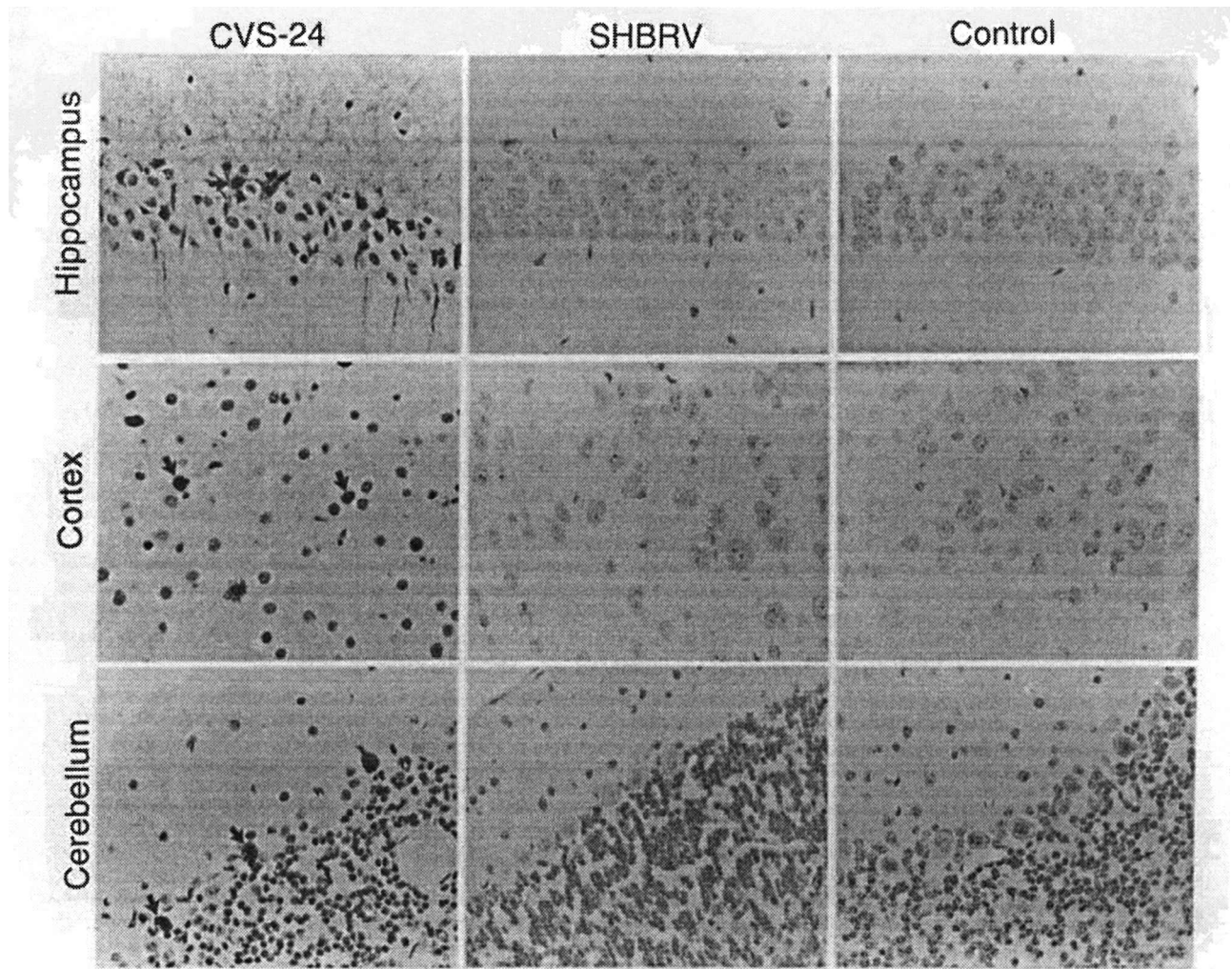


Figure 2 TUNEL staining in the CNS of mice infected with CVS-24 and SHBRV. Mice were infected with either CVS-24 or SHBRV. Mice were perfused and the brains were sectioned. Apoptosis was detected by TUNEL assay using the *in situ* cell death detection POD kit. Some of the TUNEL positive neurons are indicated by arrows (DAB with hematoxylin, 400 X).

SHBRV G, respectively. All these data suggest that the anti-G polyclonal antibody does not discriminate between the Gs of CVS-24 and SHBRV.

Northern blot hybridization indicates that the ratio between the G and the N transcripts is similar in brain tissue infected with each of the two viruses
To study if the difference in the levels of G and N antigen expression is caused by differential transcription of viral messages, Northern blot hybridization was performed using total RNA prepared from the brains infected with CVS-24 or with SHBRV. As shown in Figure 6, the levels of N and G expression are similar in animals infected with CVS-24 or with SHBRV. The ratio between N and G mRNA as determined by densitometry was on average 3.13 in animals infected with CVS-24 and 3.52 in mice infected with SHBRV, indicating the expression of N and G mRNA in CVS-24-infected animals is similar to those in SHBRV-infected animals.

Discussion

Apoptosis plays an important physiological role in normal embryonic development and tissue homeostasis (Kerr and Harmon, 1991). Apoptosis also can be induced *in vitro* and *in vivo* by a variety of viruses, including alphavirus (Lewis *et al*, 1996); flavivirus (Despres *et al*, 1998); herpesvirus (Ishii and Gobe, 1993); myxovirus (Takizawa *et al*, 1993); paramyxovirus (Esolen *et al*, 1995); picornavirus (Tolskaya *et al*, 1995); retrovirus (Laurent-Crawford *et al*, 1991); and rhabdovirus (Jackson and Rossiter, 1997). Apoptosis represents an important host defense mechanism by eliminating virus-infected cells and possibly preventing the spread of the virus to other susceptible cells (Kerr and Harmon, 1991). However, destruction of too many cells by apoptosis, particularly those nonreplenishable cells such as neurons, may result in diseases (Lewis *et al*, 1996). Indeed, the ability to induce apoptosis in neurons has been correlated

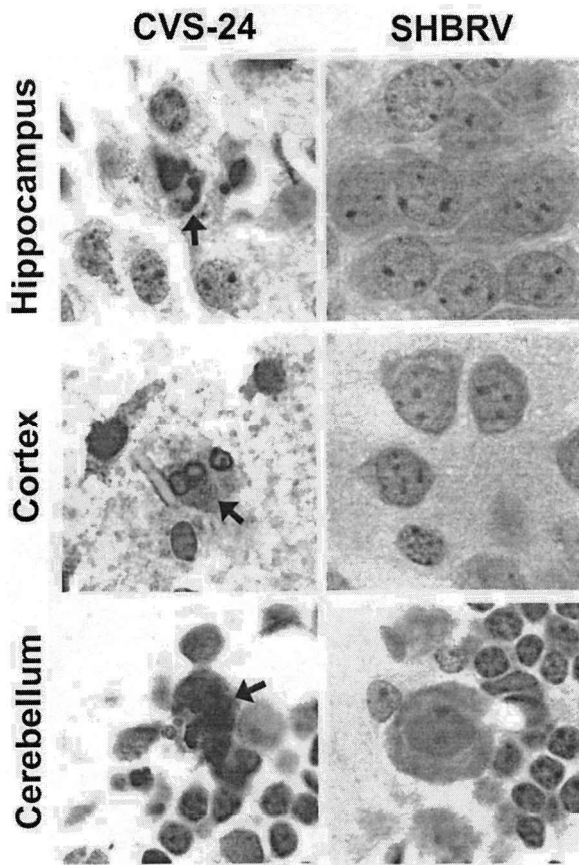


Figure 3 Multiple nuclear condensation of chromatin in neurons infected with CVS-24. Sections prepared as described in Figure 2 were observed in higher magnifications. (DAB, 1000 X.)

with neurovirulence for alphavirus and flavivirus (Lewis *et al*, 1996; Despres *et al*, 1998). Both beneficial and detrimental effects of apoptosis in rabies virus infection have been suggested. In experimental animals infected with mouse-adapted CVS virus, extensive apoptosis was observed in most parts of the CNS (Jackson and Rossiter, 1997; Theerasurakarn and Ubol, 1998). These observations led to the hypothesis that apoptosis plays an important pathogenic role in experimental rabies virus infections. However, Morimoto *et al* (1999) found that the ability of the rabies virus to induce apoptosis in primary neuronal cultures was correlated inversely with its pathogenicity in animals. These authors suggested that apoptosis plays a protective rather than damaging role in rabies virus infection. In all these studies, however, only attenuated rabies viruses were used.

In the present study, we extended the previous investigations by comparing the induction of apoptosis of a laboratory adapted CVS-24 to a street rabies virus, SHBRV. As reported by others (Jackson and Rossiter, 1997; Theerasurakarn and Ubol, 1998), extensive apoptosis was observed in many parts of the brain in some mice infected with CVS-24 as assayed by the TUNEL staining. TUNEL-positive neurons

showed typical apoptotic changes such as nuclear condensation of chromatin. TUNEL-positive neurons are localized in areas where rabies virus antigen was detected, for example, pyramidal neurons in the hippocampus and Purkinje neurons in the cerebellum. However, the most important finding of the present study is that the street rabies virus strain, SHBRV-18, does not induce apoptosis in mice. Very little or no TUNEL-positive staining was seen in the brain infected with SHBRV, despite the fact that the distribution of viral antigens in the brain was similar for both viruses. Yet, mice infected with SHBRV developed rabies at least 1 day earlier than those infected with CVS-24. Taken together, these findings may suggest that apoptosis does not play an essential role in the pathogenesis of street rabies. It is not surprising because a recent report by Camelo *et al* (2000) that the death of animals infected with CVS is not caused by CNS apoptosis. However, induction of apoptosis in mice was recently reported for a street rabies virus isolated from dogs (Ubol and Kasisith, 2000). Furthermore, CVS viruses that have been reported to induce apoptosis in primary mouse neurons (Morimoto *et al*, 1999) and in mouse models (Jackson and Rossiter, 1997; Theerasurakarn and Ubol, 1998) did not induce apoptosis in bats (Reid and Jackson, 2001). Therefore, the induction of apoptosis in neurons *in vivo* may be influenced by various factors such as the age of the host, the virus strains, the type of host, and so forth. Future studies will be needed to test if other canine as well as bat rabies virus strains has the ability to induce apoptosis in animal models as well as in the natural hosts. The ability of an individual virus to induce apoptosis should also be correlated to the different degree of virulence observed for the different rabies virus isolates (Dietzschold *et al*, 2000).

The induction of apoptosis in primary neuronal cultures by rabies virus has been correlated with the level of G expression (Morimoto *et al*, 1999). These authors (Morimoto *et al*, 1999) hypothesized that pathogenic rabies virus strains prevented apoptosis by down-regulating the expression of the G, which enables the virus to spread effectively through synaptic junctions. Recently, Morimoto *et al* (2000) further suggested that to maintain pathogenicity, the expression of rabies virus G must be strictly controlled. In the present study, we found that CVS-24 induced extensive apoptosis in the brain of mice, whereas apoptosis was not observed in mice infected with SHBRV. The G expression is not only more widespread, but the immunostaining of G is also more intense in CVS- than in SHBRV-infected mice. In contrast, the levels of N expression in CVS-infected mice were similar to, or slightly lower than in SHBRV-infected mice. Immunoprecipitation of the *in vitro* translated G by the polyclonal anti-G antibodies revealed similar reactivity of the anti-G antibodies with CVS G and SHBRV G, indicating that the differences seen in the G protein staining of CVS-24

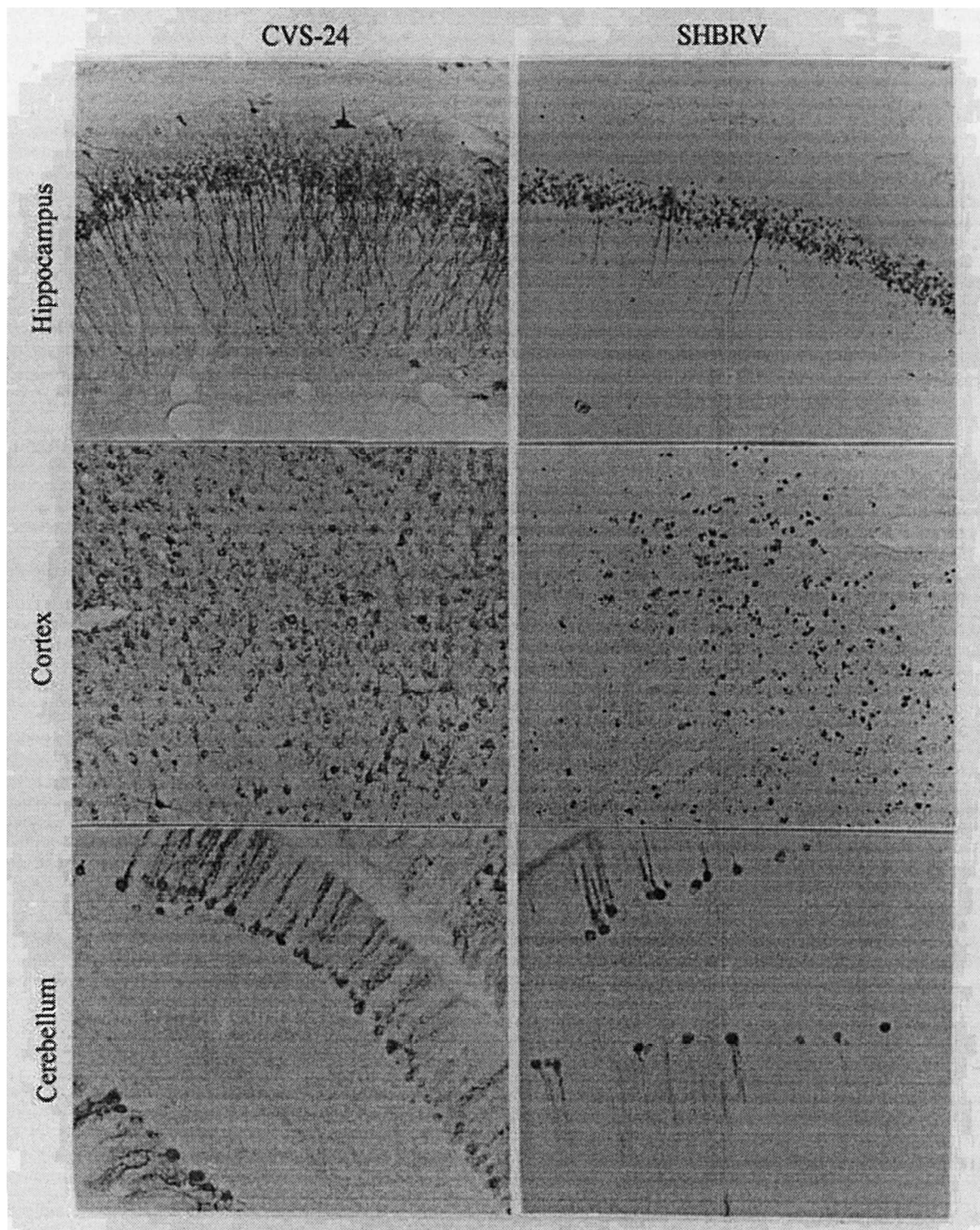


Figure 4 Distribution of rabies virus antigen (G) in the CNS. Mice were infected with either CVS-24 or SHBRV. Mice were perfused and the brains were sectioned. Rabies virus antigen (G) was detected by immunocytochemistry using anti-G polyclonal antibodies. (DAB, 200 X.)

and SHBRV-infected brains are unlikely caused by differences in affinity of the polyclonal anti-G antibodies to the different G proteins. Therefore, our findings provide *in vivo* evidence that the induction

of apoptosis indeed correlates with the level of G expression in rabies virus infections.

It has been demonstrated that the G expression by different rabies viruses in cell culture is regulated

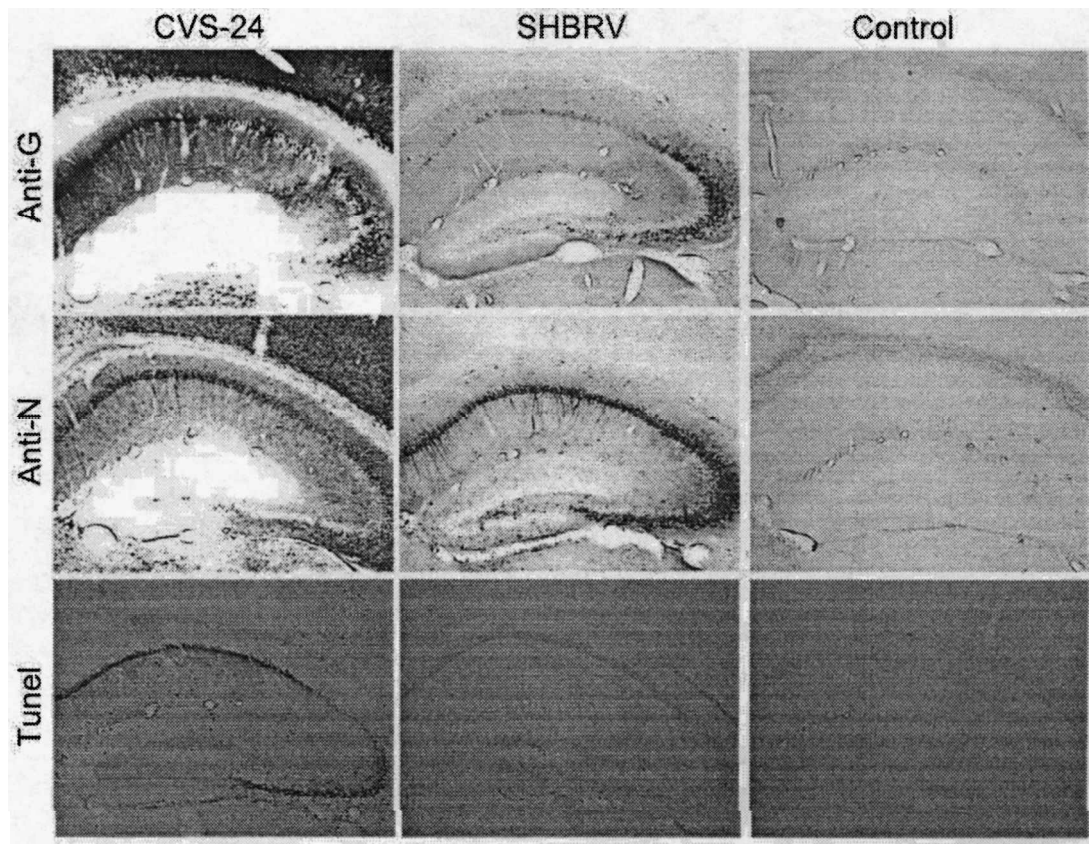


Figure 5 Comparison of rabies virus N and G expression and the induction of apoptosis in the hippocampus of mice infected with CVS-24 and SHBRV. Serial hippocampal sections from mice infected with CVS-24 or SHBRV were subjected to antigen detection using anti-G polyclonal antibodies or anti-N monoclonal antibody 802, or apoptosis detection using the *in situ* cell death detection POD kit. (DAB, 50 X.)

at the posttranslational level via protease degradation (Morimoto *et al*, 1999). To investigate if the expression of SHBRV G is regulated similarly *in vivo*, Northern blot hybridization was performed to measure the levels of both G and N mRNAs using respec-

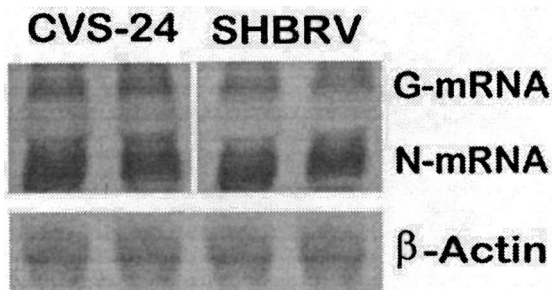


Figure 6 Expression of rabies virus N and G mRNA in the CNS of mice infected with CVS-24 and SHBRV. Total RNA was prepared from brain tissue of mice infected with CVS-24 or with SHBRV. The RNA prepared from animals infected with CVS-24 was hybridized with N and G cDNA probes prepared from CVS-N2c. The RNA prepared from animals infected with SHBRV was hybridized with N and G cDNA probes prepared from SHBRV. All the RNA preparations were also hybridized with β -actin probe.

tive G and N probes and the ratio between N and G transcripts determined. These studies showed that the levels of N and G mRNAs were similar in animals infected with CVS-24 or with SHBRV suggesting that SHBRV regulates G expression not by downregulating G mRNA transcription, but rather by posttranslational degradation.

The question how rabies virus infection of neurons causes neurological disease and death in animals and humans has puzzled investigators for more than a century (Murphy, 1985). It has long been known that human rabies patients show few gross or histopathological lesions that could explain the lethality of rabies (Murphy, 1977). In the present study, little inflammation was observed in the parenchyma of mice infected with either virus apart from a mild leptomeningitis. Neuronal necrosis and apoptosis were observed in some of the mice infected with mouse-adapted CVS-24, and only minimal apoptosis or necrosis were found in mice infected with street rabies virus variant SHBRV. The mechanism(s) by which street rabies virus infection causes neurological disease and death remains largely unresolved. Our present studies suggest that apoptosis

does not play a direct role in the pathogenesis of most street rabies virus infections and that other pathologic processes, particularly impairment of neuronal functions (Tsiang, 1982), may contribute to the profound CNS dysfunction characteristic of rabies. It is possible that one of the mechanisms by which street rabies viruses induce neurological diseases is by evading innate and adoptive host defense mechanisms such as apoptosis and antigen presentation. In this context, it has been shown that apoptotic bodies have an exceptional ability to present immunogens to antigen presenting cells and thereby enhance antiviral immune responses (Sasaki *et al*, 2001).

Materials and methods

Cells, animals, and viruses

ICR mice were housed in temperature- and light-controlled quarters. They had access to food and water *ad libitum*. Three groups of mice (10 in each group) 5 to 6 weeks of age were selected. One group was left uninfected, and the other two groups were infected intracerebrally (i.c.) with 2×10^5 focus forming unit (ffu) of either CVS-24 or SHBRV. The CVS-24 was prepared by passaging the virus in suckling mouse brain as described previously (Morimoto *et al*, 1998). The SHBRV (SHBRV-18) was isolated from a human patient and passaged in suckling mice as described previously (Dietzschold *et al*, 2000). After infection, mice were observed daily for 10 days for clinical signs of rabies. When moribund, mice (eight in each group) were anaesthetized and perfused transcardially with 10% neutral buffered formalin. After perfusion, the brains were removed for either immunocytochemistry (four mice each group) or histopathology (four mice each group). Alternatively, mice (two in each group) were euthanized, and brains were removed and immediately frozen for RNA extraction and Northern blot hybridization.

Immunocytochemistry for the detection of rabies virus antigens

The perfused brains were fixed with 10% formalin for 3 days and coronal sections (50- μ m thickness) were prepared by slicing the brains with a Vibratome (TPI, St. Louis, MO). These sections were subjected to immunocytochemical staining following the procedure routinely used for detecting pseudorabies virus antigens (Weiss and Chowdhury, 1998) using the VectaStain ABC kit (Vector Laboratories, Burlingame, CA). The primary antibody used was either the monoclonal antibody 802-2 directed against rabies virus nucleoprotein (N) (Harmir *et al*, 1995) or the rabbit polyclonal anti-rabies virus glycoprotein (G) antibody (Fu *et al*, 1993a). The secondary antibody used was biotinylated goat anti-mouse or goat anti-rabbit IgG from the VectaStain kits. The avidin-biotin-peroxidase complex (ABC) then was used to localize the biotinylated antibody. Finally diaminobenzidine

(DAB) was used as a substrate for color development. The positively stained cells had a dark brown reaction product over the nucleus and cytoplasm under a light microscope.

Histopathology

For histopathology, the perfused mouse brains were dehydrated through a graded series of ethanol and embedded in paraffin. Paraffin sections of 4- μ m thickness were prepared and stained with hematoxylin and eosin.

Detection of apoptosis in vivo

Apoptosis in the brains of infected mice was detected with a TUNEL assay by using the *in situ* cell death detection POD kit (Boehringer Mannheim, Germany). The TUNEL assay was performed according to the manufacturer's specifications. Briefly, tissue sections (paraffin or floating sections) were treated with proteinase K (20 μ g/ml) and then incubated with 3% H₂O₂ for 10 min at room temperature. After sections were washed, the TUNEL reaction mixture was added. After incubation overnight at 4°C, the sections were rinsed and incubated with converter-POD for 2 h at room temperature. Finally, DAB-substrate solution was added to the sections for color development. The floating sections were mounted onto slides, air-dried, and coverslipped. The paraffin sections were counterstained with hematoxylin.

In vitro translation, immunoprecipitation, and PAGE analysis of G protein

Full-length cDNAs for CVS-N2c and SHBRV G proteins were synthesized by reverse transcription-polymerase chain reaction (RT-PCR) as described (Morimoto *et al*, 2000). After amplification and digestion with XhoI-XbaI, the cDNA fragments were cloned into XhoI-XbaI sites of pCI mammalian expression vector. Recombinant plasmids containing G proteins were amplified with plasmid specific primers. After sequencing, PCR products were transcribed/translated using *in vitro* TnT Quick Coupled Transcription/Translation System (Promega, Madison, WI). Briefly, PCR-generated fragments containing the T7 promoter were added together with [³⁵S] methionine to the TnT Quick Master Mix and incubated in a 50- μ l reaction volume for 90 min at 30°C. The synthesized proteins were used for TCA precipitation and immunoprecipitation. TCA precipitation was performed according to the TnT Quick Coupled Transcription/Translation System technical manual. Immunoprecipitation was carried out at 4°C overnight using a rabbit anti-rabies G antibody (Fu *et al*, 1993a). The resulting immune complexes were bound to Protein A agarose (Life Technologies, Gaithersburg, MD) and analyzed by 10% SDS-PAGE. Following electrophoresis, the gel was dried and protein bands were visualized and quantitatively analyzed using a phosphorimager.

Northern blot hybridization

Total RNA was extracted from brain tissue as described previously (Fu *et al*, 1993b). For Northern blot hybridization, total RNA was denatured with a 10 mM sodium phosphate buffer (pH 7.4) containing 50% (v/v) formamide at 65°C for 15 min and electrophoresed on a 1.2% agarose gel containing 1.1 M formaldehyde and 10 mM sodium phosphate. Full-length N and G cDNAs for CVS-N2c and SHBRV were synthesized by RT-PCR as described (Morimoto *et al*, 2000) and were used to make nick-translated N and G

probes for Northern blot hybridization. For quantitative analysis, the intensity of the hybridization bands was measured by densitometry.

Acknowledgements

This work was supported partially by Public Health Service grant AI-33029 (Z.F.F.) and AI-45097 (B.D.) from the National Institute of Allergy and Infectious Diseases.

References

- Camelo S, Lafage M, Lafon M (2000). Absence of the p55 Kd TNF- α receptor promotes survival in rabies virus acute encephalitis. *J NeuroVirol* **6**: 507–518.
- Constantine DG (1962). Rabies transmitted by non-bite route. *Pub Health Rep* **77**: 287–289.
- Despres P, Frenkiel MP, Ceccaldi PE, Duarte Dos Santos C, Deubel V (1998). Apoptosis in the mouse central nervous system in response to infection with mouse-neurovirulent dengue viruses. *J Virol* **72**: 823–829.
- Dietzschold B, Morimoto K, Hooper DC, Smith JS, Rupprecht CE, Koprowski H (2000). Genotypic and phenotypic diversity of rabies virus variants involved in human rabies: implications for post-exposure prophylaxis. *J Hum Virol* **3**: 50–57.
- Dietzschold B, Rupprecht CE, Fu ZF, Koprowski H (1996). Rhabdoviruses. In: *Fields' Virology*, 3rd edn, Fields B, Knipe D, Howley PM, *et al.* (eds). Lippincott-Raven Press: Philadelphia, pp 1137–1159.
- Esolen LM, Park SW, Hardwick JM, Griffin DE (1995). Apoptosis as a cause of death in measles virus-infected cells. *J Virol* **69**: 3955–3958.
- Fu ZF, Rupprecht R, Dietzschold B, Saikumar P, Niu HS, Babka I, Wunner WH, Koprowski H (1993a). Oral vaccination of raccoons (*Procyon lotor*) with baculovirus-expressed rabies virus glycoprotein. *Vaccine* **11**: 925–928.
- Fu ZF, Weihe E, Zheng YM, Schafer MK, Sheng H, Corisdeo S, Rauscher FJ 3d, Koprowski H, Dietzschold B (1993b). Differential effects of rabies and Borna disease viruses on immediate-early- and late-response gene expression in brain tissues. *J Virol* **67**: 6674–6681.
- Galelli A, Baloul L, Lafon M (2000). Abortive rabies virus central nervous infection is controlled by T lymphocyte local recruitment and induction of apoptosis. *J NeuroVirol* **6**: 359–372.
- Harmir AN, Moser G, Fu ZF, Dietzschold B, Rupprecht CE (1995). Immunohistochemical test for rabies: identification of a diagnostically superior monoclonal antibody. *Vet Rec* **136**: 295–296.
- Hemachudha T (1994). Human rabies: clinical aspects, pathogenesis, and potential therapy. *Curr Top Microbiol Immunol* **187**: 121–143.
- Ishii HH, Gobe GC (1993). Epstein-Barr virus infection is associated with increased apoptosis in untreated and phorbol ester-treated human Burkitt's lymphoma (AW-Ramos) cells. *Biochem Biophys Research Commun* **192**: 1415–1423.
- Iwasaki Y (1991). Spread of virus within the central nervous system. In: *The Natural History of Rabies*, 2nd edn., Baer, GM (ed). CRC press: Boca Raton, FL, pp 121–132.
- Jackson AC, Park H (1998). Apoptotic cell death in experimental rabies in suckling mice. *Acta Neuropathol* **95**: 159–164.
- Jackson AC, Rossiter JP (1997). Apoptosis plays an important role in experimental rabies virus infection. *J Virol* **71**: 5603–5607.
- Kerr JFR, Harmon BV (1991). Definition and incidence of apoptosis: an historical perspective. In: *Apoptosis: The Molecular Basis of Cell Death*. Tomei LD, and Cope FO (eds). Cold Spring Harbor, New York: Cold Spring Harbor Laboratory Press: Cold Spring Harbor, NY, pp 5–9.
- Laurent-Crawford AG, Krust B, Muller S, Riviere Y, Rey-Cuille MA, Bechet JM, Montagnier L, Hovanessian AG (1991). The cytopathic effect of HIV is associated with apoptosis. *Virology* **185**: 829–839.
- Lentz TL, Burrage TG, Smith AL, Crick J, Tignor GH (1982). Is the acetylcholine receptor a rabies virus receptor? *Science* **215**: 182–184.
- Lewis J, Wesselingh SL, Griffin DE, Hardwick JM (1996). Alphavirus-induced apoptosis in mouse brains correlates with neurovirulence. *J Virol* **70**: 1828–1835.
- Miyamoto K, Matsumoto S (1967). Comparative studies between pathogenesis of street and fixed rabies infection. *J Exp Med* **125**: 447–456.
- MMWR (2000). Human rabies—California, Georgia, Minnesota, New York, and Wisconsin, 2000. *MMWR Mort Morb Wkly Rep* **49**: 1111–1115.
- Morimoto K, Foley HD, McGettigan JP, Schnell MJ, Dietzschold B (2000). Reinvestigation of the role of the rabies virus glycoprotein in viral pathogenesis using a reverse genetics approach. *J NeuroVirol* **6**: 373–381.
- Morimoto K, Hooper DC, Carbaugh H, Fu ZF, Koprowski H, Dietzschold B (1998). Rabies virus quasispecies: implication for pathogenesis. *Proc Natl Acad Sci USA* **95**: 3152–3156.
- Morimoto K, Hooper DC, Spitsin S, Koprowski H, Dietzschold B (1999). Pathogenicity of different rabies virus variants inversely correlates with apoptosis and rabies virus glycoprotein expression in infected primary neuron cultures. *J Virol* **73**: 510–518.
- Murphy FA (1977). Rabies pathogenesis. *Arch Virol* **54**: 279–297.
- Murphy FA (1985). The pathogenesis of rabies virus infection. In: *World's Debt to Pasteur*. Plotkin SA, Koprowski H (eds). Alan Liss: New York, pp 153–169.

- Reid JE, Jackson AC (2001). Experimental rabies virus infection in *Artibeus jamaicensis* bats with CVS-24 variants. *J NeuroVirol*. In press.
- Sasaki S, Amara RR, Oran AE, Smith JM, Robinson HL (2001). Apoptosis-mediated enhancement of DNA-raised immune responses by mutant caspases. *Nat Biotech* **19**: 543–547.
- Smart NL, Charlton KM (1992). The distribution of challenge virus standard rabies virus versus skunk street rabies virus in the brains of experimentally infected rabid skunks. *Acta Neuropathol* **84**: 501–508.
- Takizawa T, Matsukawa S, Higuchi Y, Nakamura S, Nakanishi Y, Fukuda R (1993). Induction of programmed cell death (apoptosis) by influenza virus infection in tissue culture cells. *J Gen Virol* **74**: 2347–2355.
- Theerasurakarn S, Ubol S (1998). Apoptosis induction in brain during the fixed strain of rabies virus infection correlates with onset and severity of illness. *J NeuroVirol* **4**: 407–414.
- Thoulouze MI, Lafage M, Montano-Hirose JA, Lafon M (1997). Rabies virus infects mouse and human lymphocytes and induces apoptosis. *J Virol* **71**: 7372–7380.
- Thoulouze MI, Lafage M, Schachner M, Hartmann U, Cremer H, Lafon M (1998). The neural cell adhesion molecule is a receptor for rabies virus. *J Virol* **72**: 7181–7190.
- Tirawatnpong S, Hemachudha T, Manutsathit S, Shuangshoti S, Phanthumchinda K, Phanuphak P (1989). Regional distribution of rabies viral antigen in central nervous system of human encephalitic and paralytic rabies. *J Neurol Sci* **92**: 91–99.
- Tolskaya EA, Romanova LI, Kolesnikova MS, Ivannikova TA, Smirnova EA, Raikhlin NT, Agol VI (1995). Apoptosis-inducing and apoptosis-preventing functions of poliovirus. *J Virol* **69**: 1181–1189.
- Tsiang H (1982). Neuronal function impairment in rabies infected rat brain. *J Gen Virol* **61**: 277–281.
- Tuffereau C, Benejean J, Blondel D, Kieffer B, Flamand A (1998). Low-affinity nerve-growth factor receptor (P75NTR) can serve as a receptor for rabies virus. *EMBO J* **17**: 7250–7259.
- Ubol S, Kasisith J (2000). Reactivation of Nedd-2, a developmentally down-regulated apoptotic gene, in apoptosis induced by a street strain of rabies virus. *J Med Microbiol* **49**: 1043–1046.
- Weiss ML, Chowdhury SI (1998). The renal afferent pathways in the rat: a pseudorabies virus study. *Brain Res* **812**: 227–241.